

URINARY SYSTEM LAB EXERCISES 24, 25, 26 & 27

Dr. Lisa Brinn

Video Recording Links of Lab Models

- [A&P II Module 10 Kidney](#)
- [A&P II Module 10 Nephron](#)
- [A&P II Module 10 Renal Corpuscle](#)
- [A&P II Module 10 Comparing Male and Female Urinary Systems](#)

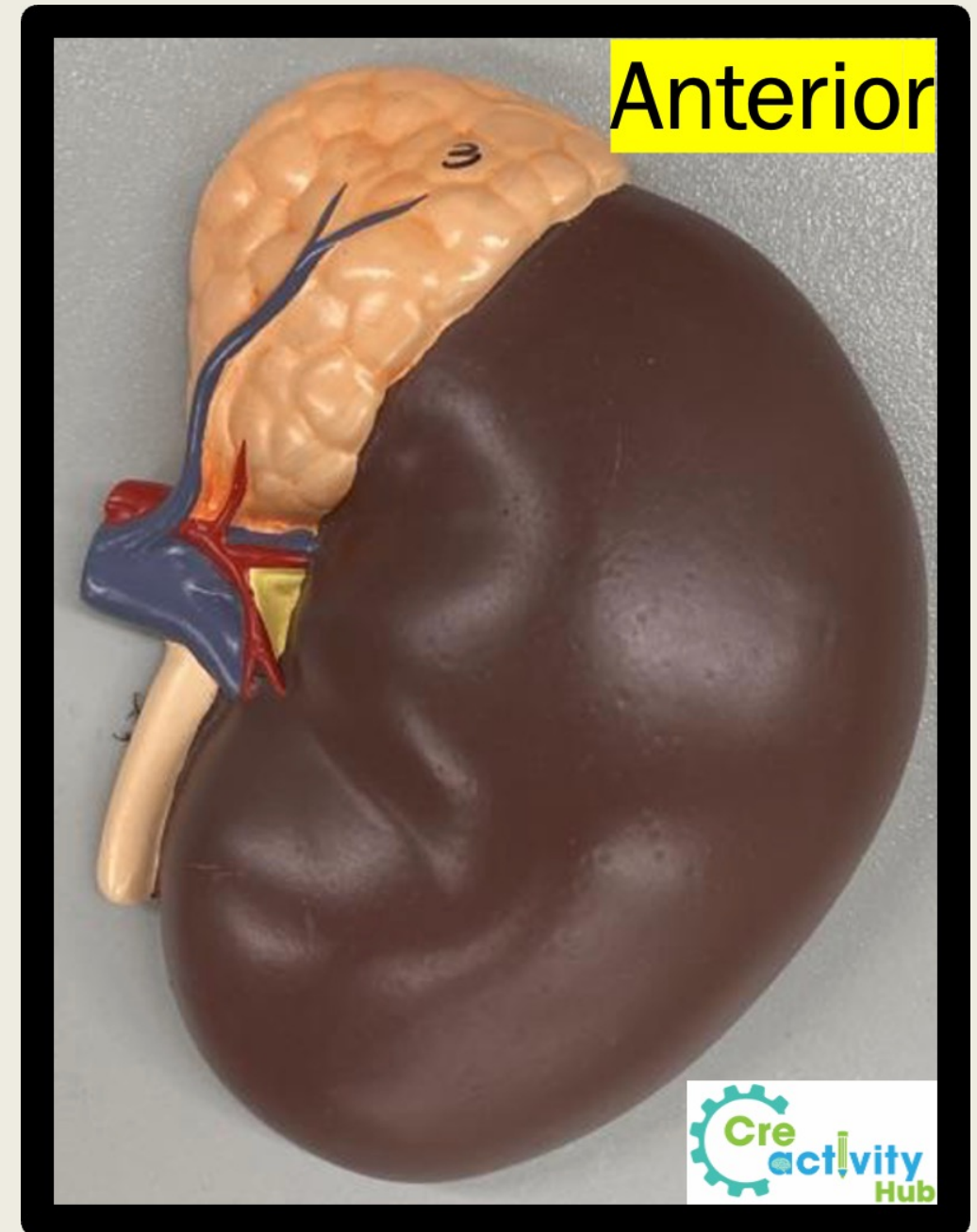
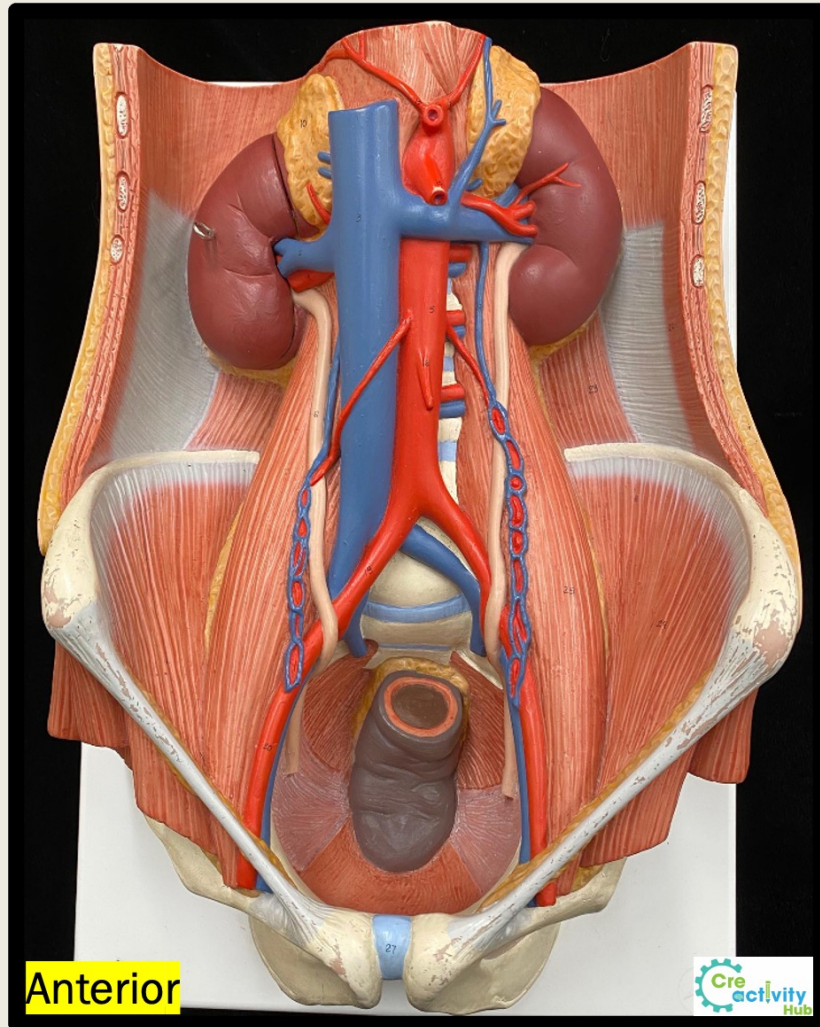
Kidney Terminology List

- Fibrous capsule
- Major calyx
- Minor calyx
- Renal papilla
- Renal pelvis
- Renal pyramid

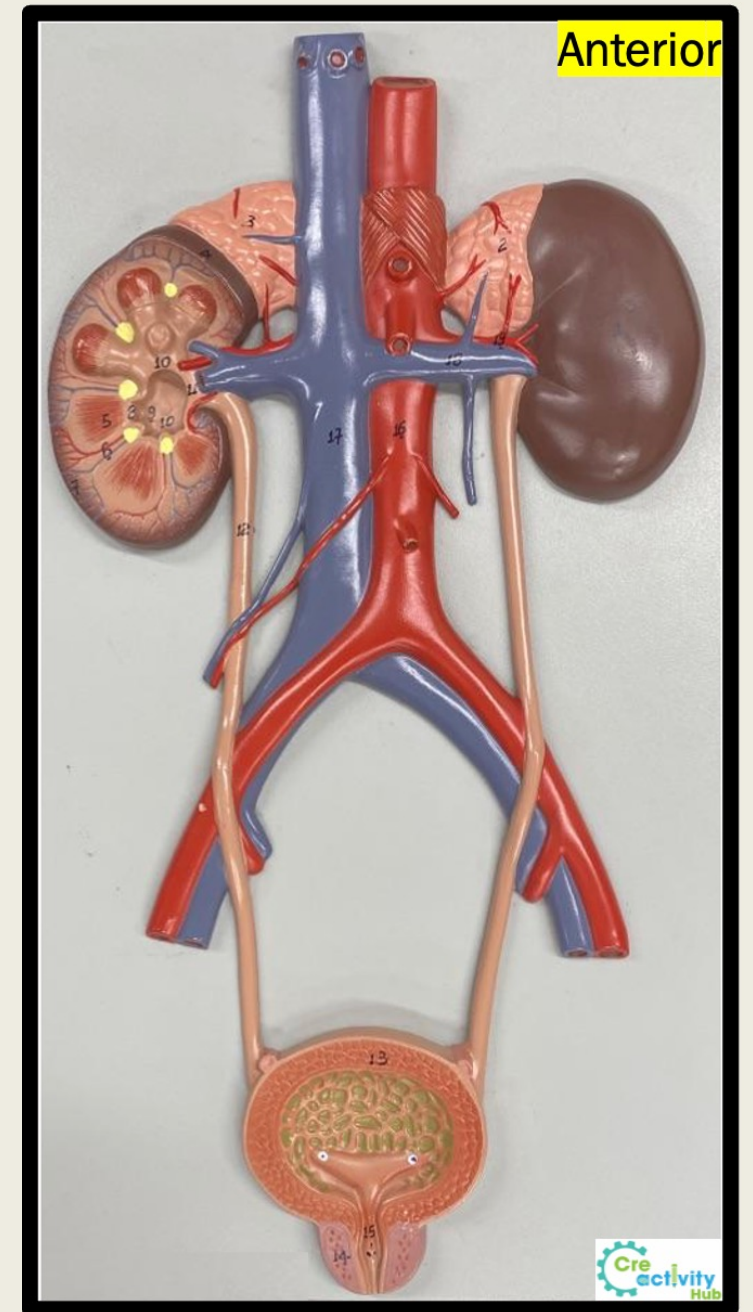
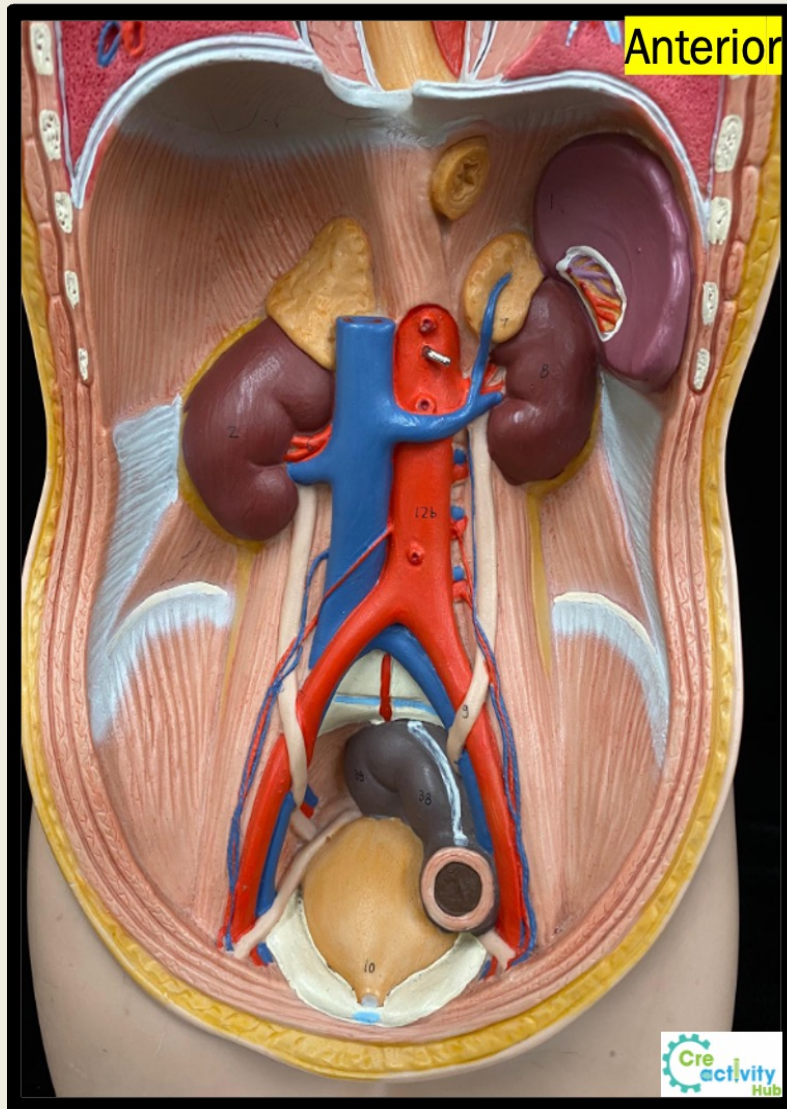
Other structures

- Adipose tissue
- Renal artery
- Renal vein
- Trigone
- Ureter
- Urethra
- Urinary bladder

Kidneys



Kidney and Other Structures



Nephron Terminology List

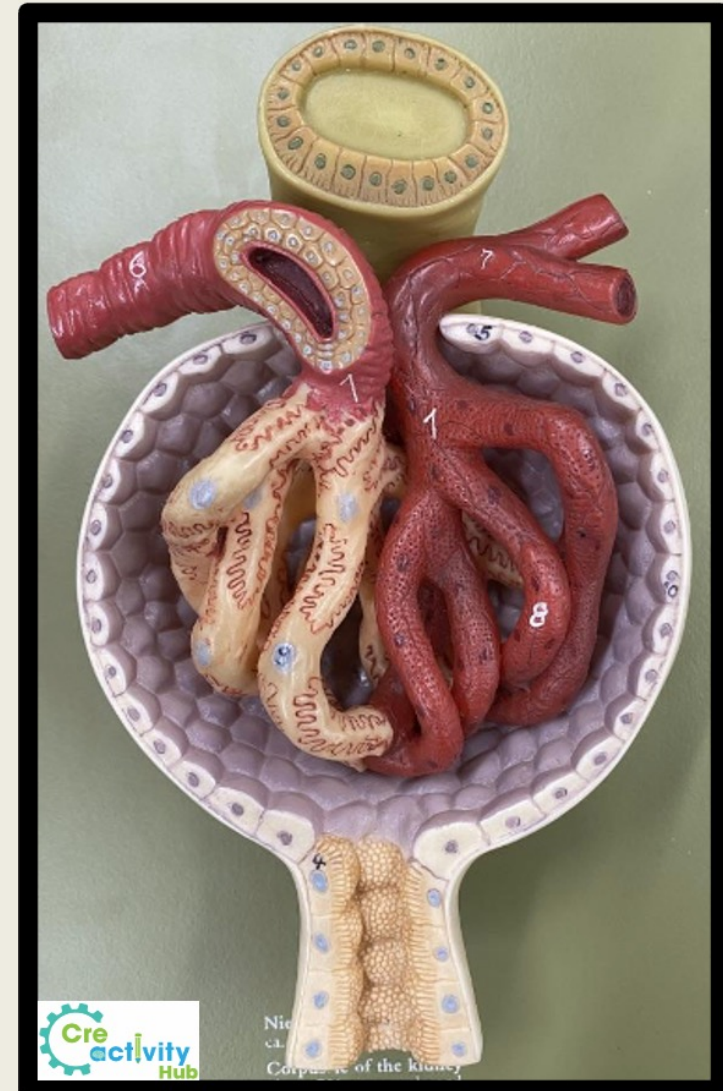
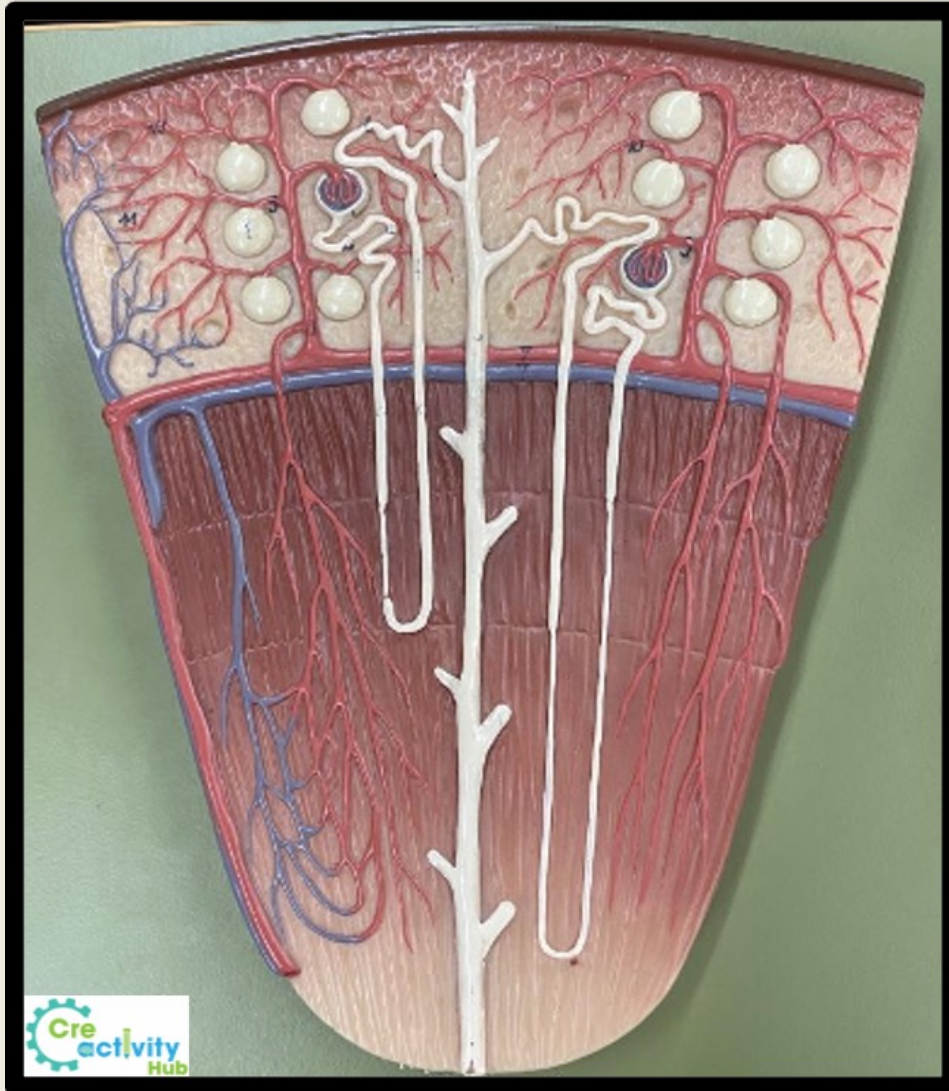
(you may choose just one answer when there are multiple acceptable terms)

- Afferent arteriole
- Capsular space
- Collecting duct
- Connecting tubule
- Cortical radiate arteries
- Distal convoluted tubule
- Efferent arteriole
- Glomerular capsule or Bowman's capsule
- Glomerulus
- Juxtaglomerular cells
- Macula densa
- Microvilli
- Podocytes
- Proximal convoluted tubule
- Renal corpuscle
- Thick ascending limb
- Thin ascending limb
- Thick descending limb
- Thin descending limb
- Vasa recta

Other terms

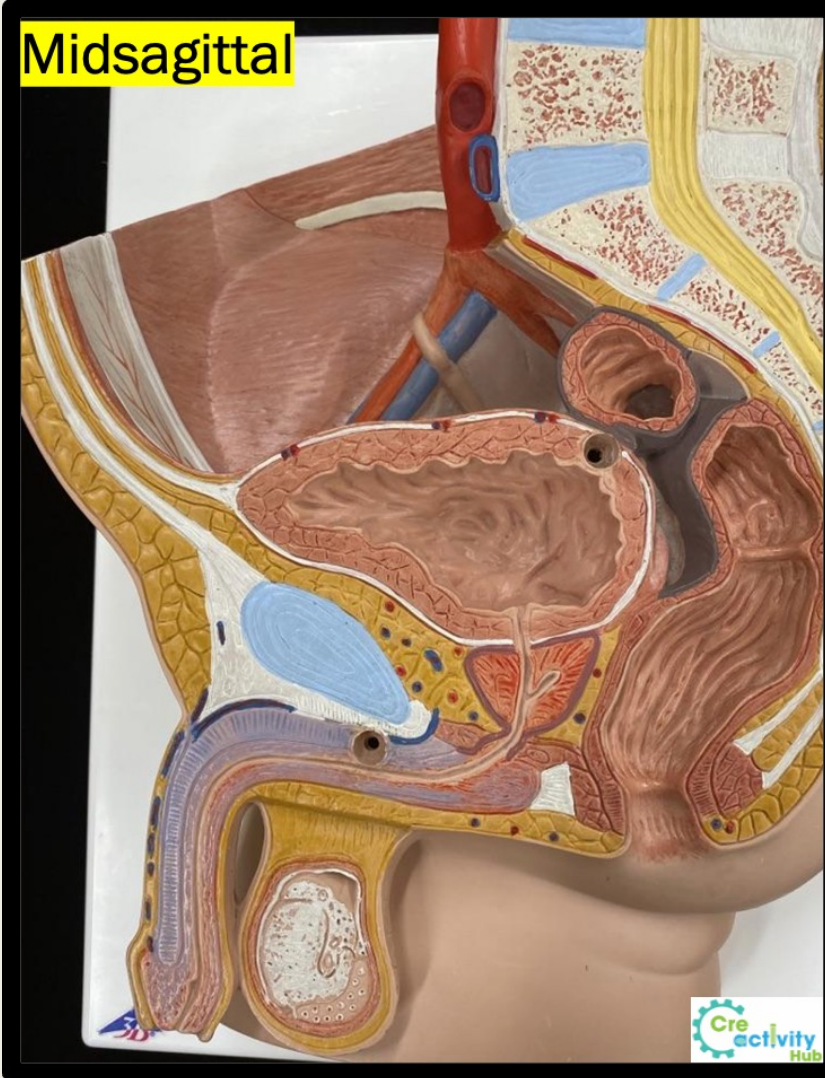
- Aldosterone
- Antidiuretic hormone
- Erythropoietin
- Filtrate or glomerular filtrate
- Renin
- Simple cuboidal epithelium
- Simple squamous epithelium

Nephron and Other Structures

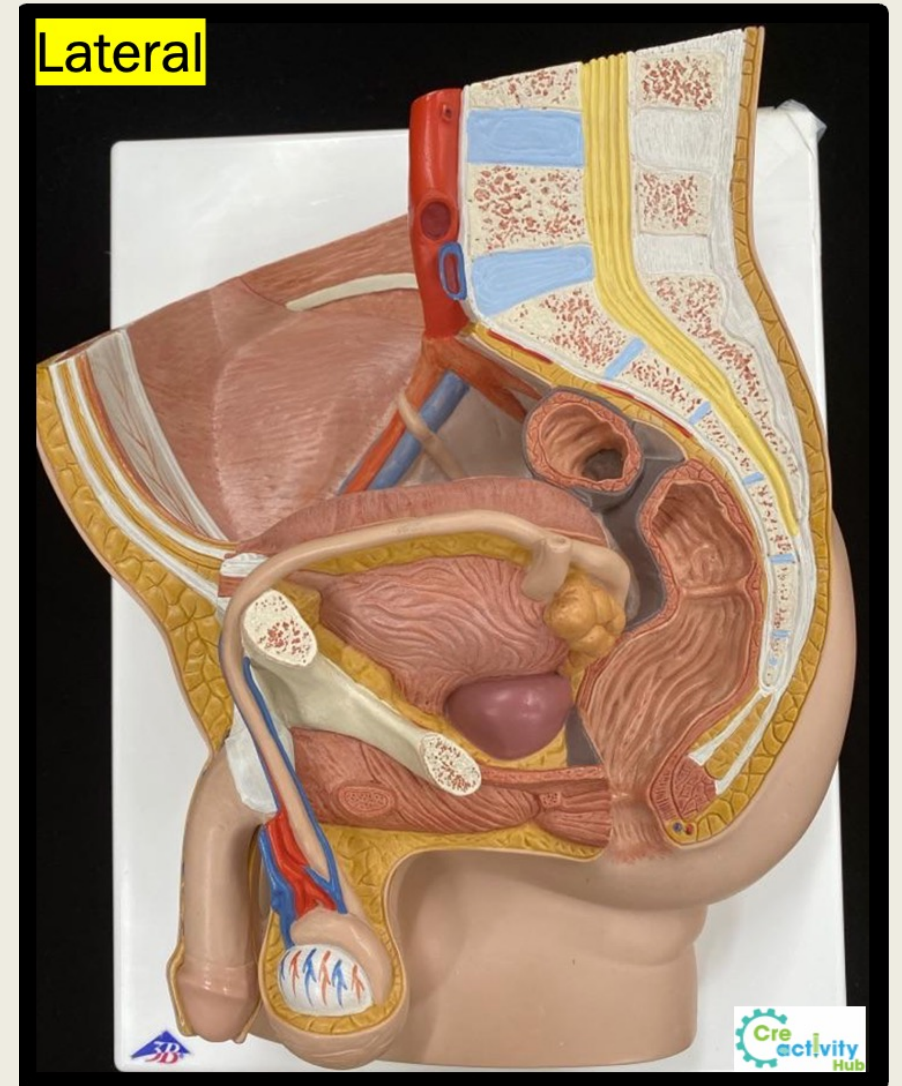


Male X Female Urinary System

Midsagittal

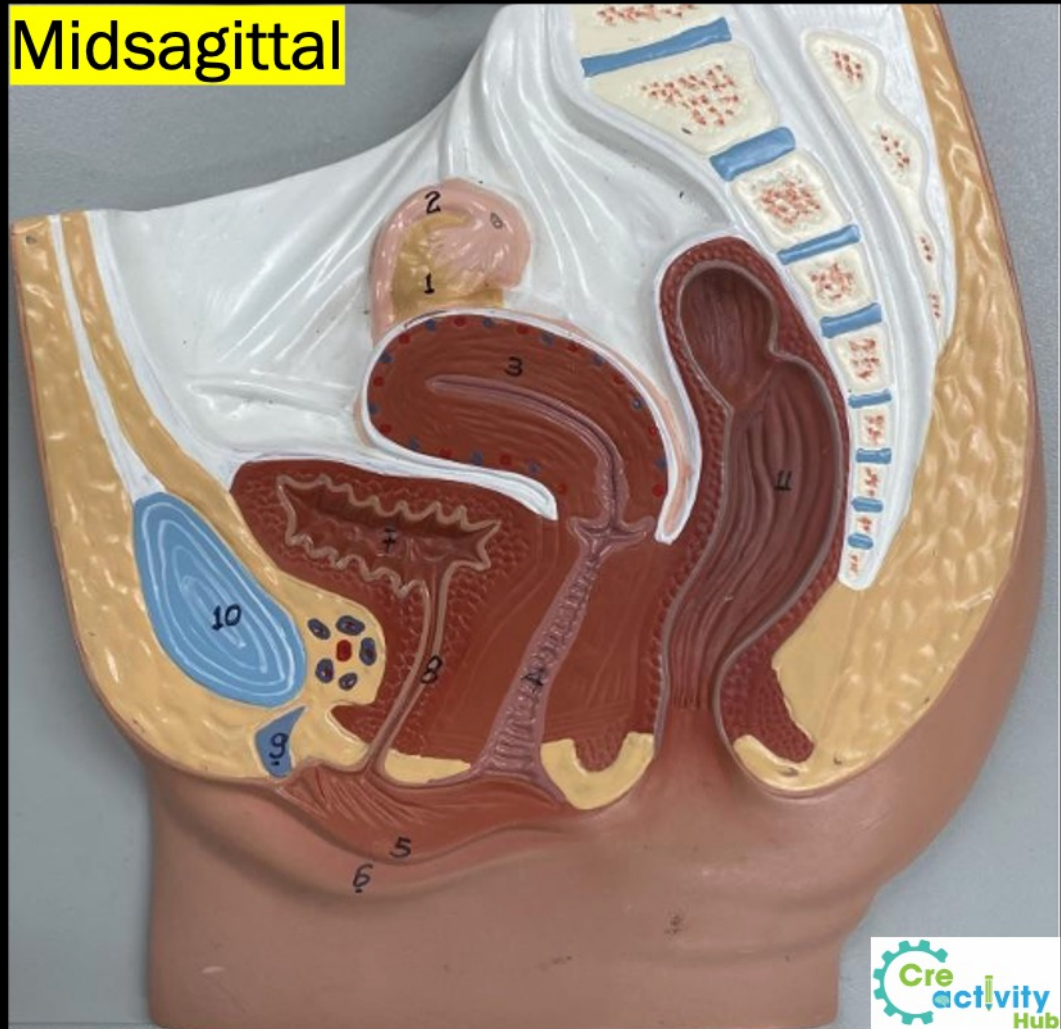


Lateral



Male X Female Urinary System

Midsagittal



Midsagittal

